

Case Study: Ashley

Congenital Scoliosis w/ Hemivertebra & Wedge Vertebra
6 years to 7 years

David S. Feldman, MD

Chief of Pediatric Orthopedic Surgery

Professor of Orthopedic Surgery & Pediatrics

NYU Langone Medical Center & NYU Hospital for Joint Diseases

BACKGROUND

At the age of 6, Ashley's mother noticed a curve in her spine and her pediatrician referred them to orthopedic doctors for further evaluation.

MRIs and x-rays showed a 30 degree curve in her spine (scoliosis) along with a vertebra that was undeveloped on one side (hemivertebra). There was no family history of either scoliosis or kyphosis.

DIAGNOSIS

During my examination of Ashley, I confirmed the previous findings and diagnosed:

- Hemivertebra at Lumbar 1 vertebra (L1)
- Decompensation (curving) of the trunk towards one side due to hemivertebra
- Congenital wedge vertebra (deformed vertebra) at Lumbar 5 vertebra (L5)

Figure 1

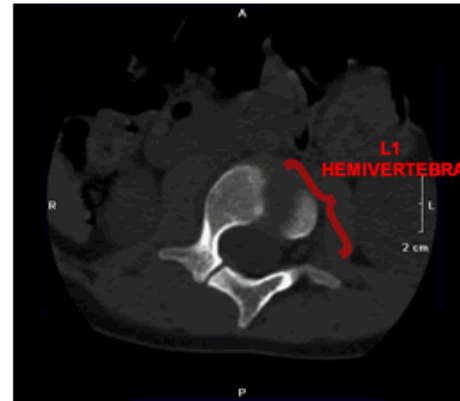
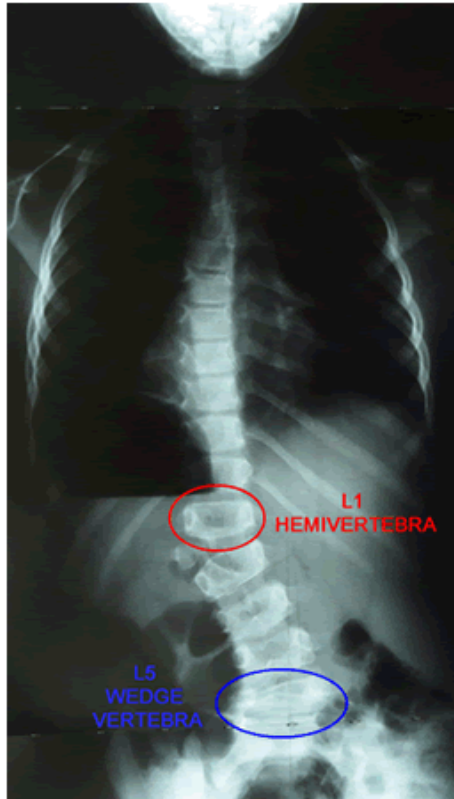

Figure 2

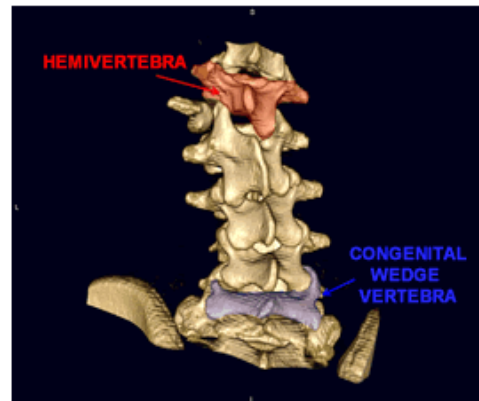


Figure 3

Fig 1. Anterior x-ray of Ashley's spine.

Fig 2. A cross section MRI of Ashley's L1 vertebra.

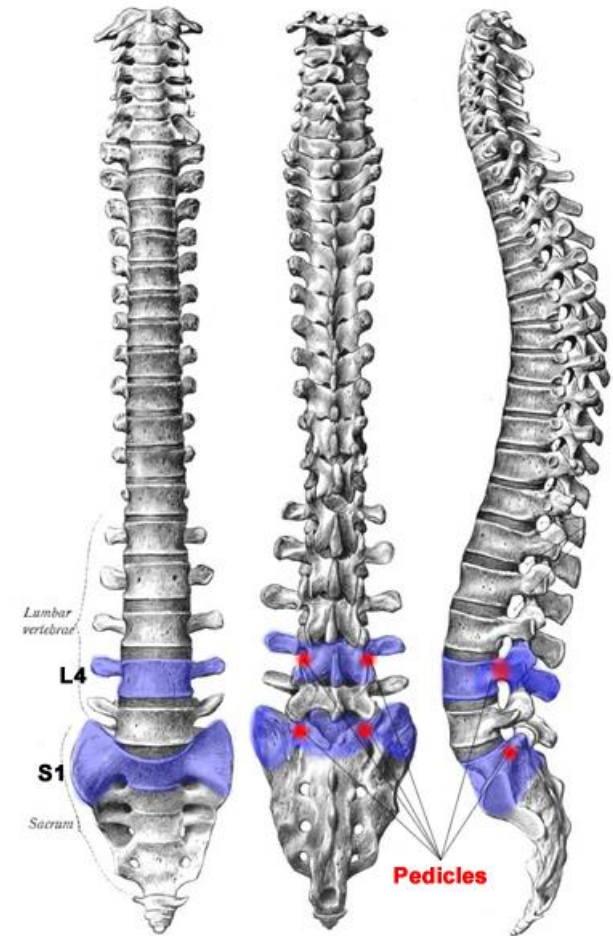
Fig 3. A posterior CT Scan of Ashley's lumbar vertebrae.

TREATMENT

While non-surgical bracing is an option in some cases of scoliosis, it is ineffective in cases such as this where a hemivertebra is causing a progressive deformity. As a result, surgery was performed to straighten Ashley's spine, realign her trunk, and prevent further progression of her scoliosis.

Posterior Spinal Fusion

An incision was made from the base of Ashley's L4 to S1 vertebra. A titanium XIA 4.5 implant was affixed with screws to the L4 and S1 pedicles to fuse the two levels together preventing further progression of Ashley's curve.



Screws were not affixed to the L5 because the L4 to S1 fusion provided sufficient fixation. The L1 hemivertebra was stabilized by the lower spinal fusion and was to be observed rather than surgically altered.

Osteotomy

A wedge of bone was removed from the right side of her L5 vertebra to correct the deformity.

To aid healing and prevent infection, closure of the wound was completed by Dr. Michael Margiotta of Plastic Surgery.

Post Op Treatment

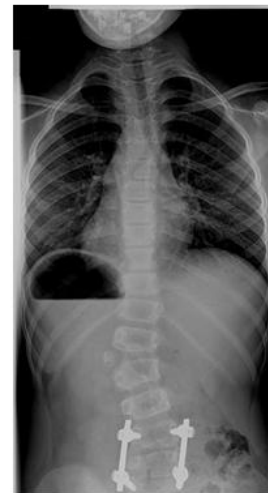- To prevent infection, a course of antibiotics began during the operation and continued for two weeks after surgery.
- Due to the wedge resection of her vertebra, Ashley used a wheelchair for 6 weeks and a brace for 6 months to protect her body while she healed.
- After surgery Ashley came into the office every six months and then once per year for follow-ups.



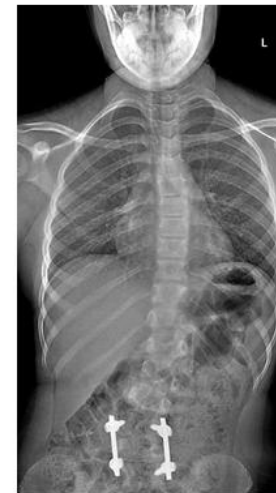Ashley in her reclining wheelchair after surgery.

CONCLUSION

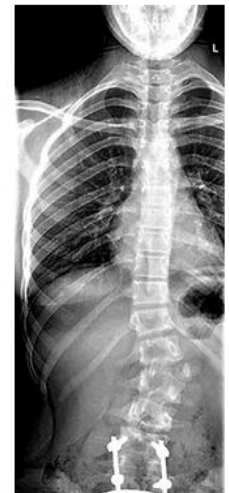The temporary brace and permanent internal hardware stabilized Ashley's hemivertebra, halting the progression of her scoliosis, and keeping her curve in the range of 20 to 25 degrees even as she grew.



1.5 Years



2.5 Years



3.5 Years

Ashley is now a champion freestyle swimmer with no physical limitations.



David S. Feldman, MD

Pediatric Orthopedic Surgeon

www.davidsfeldmanmd.com