

Case Study: Grace

Varus Ankle & Medial Physeal Bar

12 years to 13 years

David S. Feldman, MD

Chief of Pediatric Orthopedic Surgery

Professor of Orthopedic Surgery & Pediatrics

NYU Langone Medical Center & NYU Hospital for Joint Diseases

BACKGROUND

At the age of 10, Grace dislocated and fractured her right ankle during gymnastics. She underwent surgery at another facility to repair the injury which had also affected her growth plate (physis) and heel. After surgery, she was placed in short leg casts for six weeks, made a full recovery, and was able to return to gymnastics.

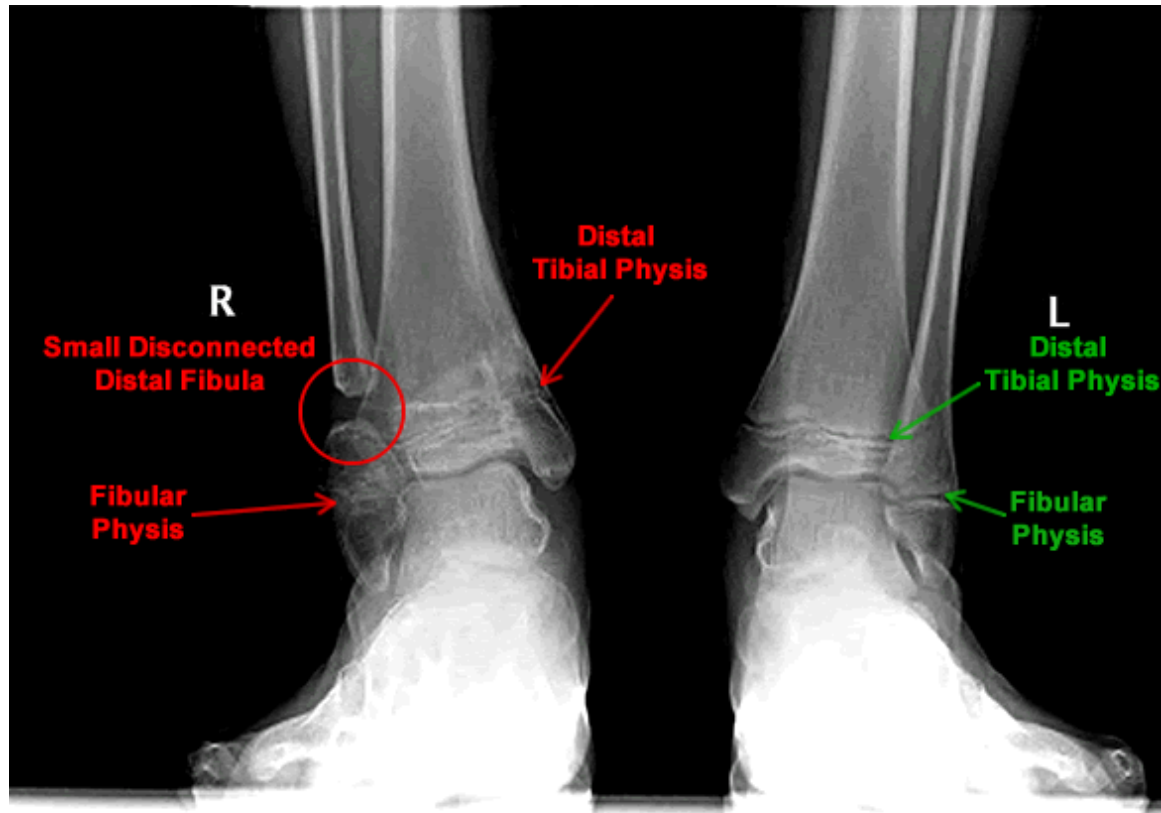
A few months before her 12th birthday, Grace's mother noticed her right foot had begun to turn outward. Her pediatrician ordered CT scans and MRIs for evaluation and found that a bony bridge had developed in her physis (physeal bar).

Another surgery was performed to remove a portion of her fibula along with the bony bridge as it would have likely delayed or prevented further growth of the bone. She was able to return to gymnastics after surgery but began to feel pain in her instep along with ongoing numbness and tingling in her heel.

A few months after her second surgery,
Grace visited me for a second opinion on
her right ankle.

EVALUATION

During our first appointment, I examined Grace and reviewed her medical films. I found that her physis seemed to have stopped growing and as a result of her previous surgeries, there was only a small distal fibula remaining near her ankle and it was not attached to the rest of her fibula.

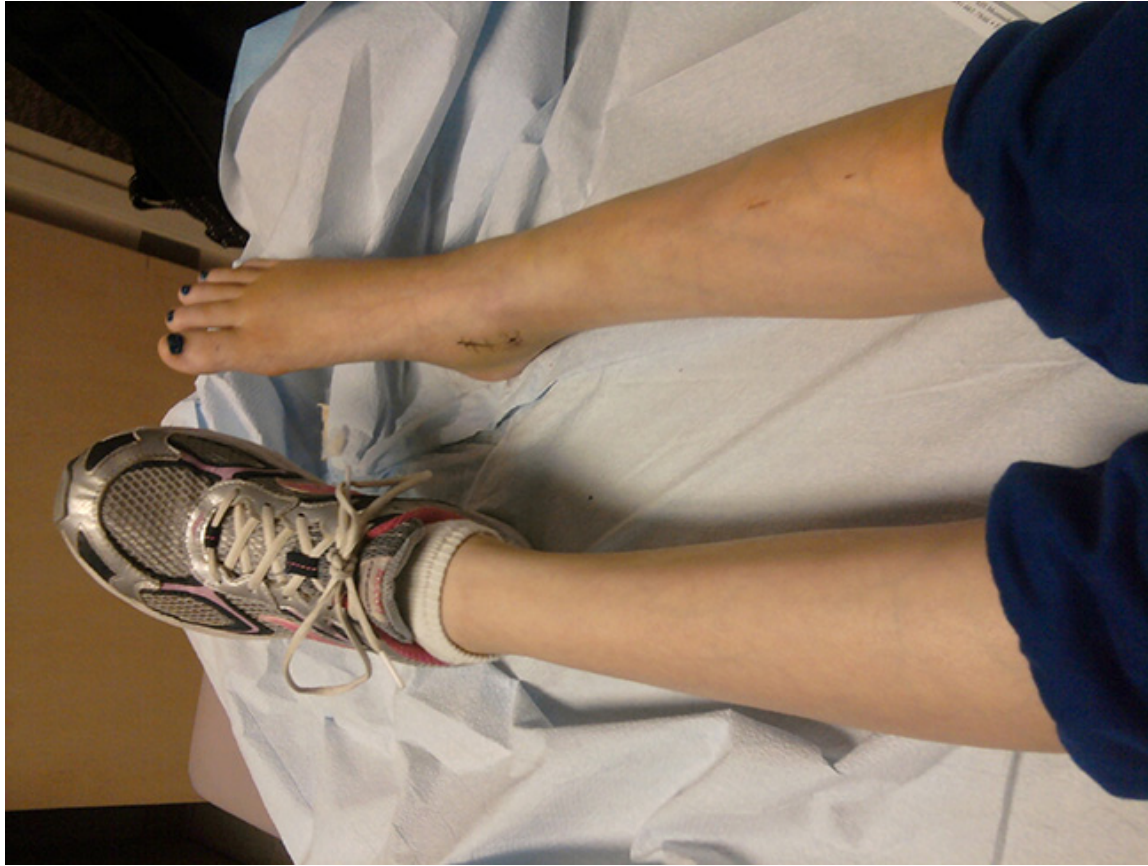

An x-ray of Grace's lower limbs. Note the right limb's lack of space around the physes and the disconnected parts of the fibula.

I was concerned that this small amount of bone would be insufficient to buttress and protect her ankle. In addition, the ankle was bowing (varus) and surgery would become a necessity if it continued to drift into a more varus position.

TREATMENT

Grace began physical therapy for treatment of muscle atrophy in her ankle which helped to decrease her pain and stopped the tingling in her heel. However, over the next few months her ankle varus increased and the range of motion in her ankle mildly decreased. The physseal bar also reappeared in her ankle and required surgical intervention to prevent bone growth issues in her leg.



Grace's ankle before surgery

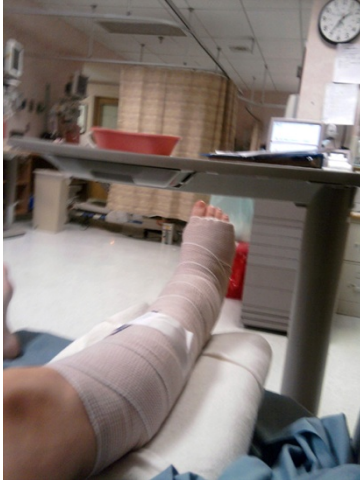Distal Tibia Epiphysiodesis

A small incision was made at the distal tibia and the entire lateral distal tibial physis as well as the physis of the medial and lateral fibula were removed. The surgical site was irrigated, closed in layers, and dry sterile dressings were applied.

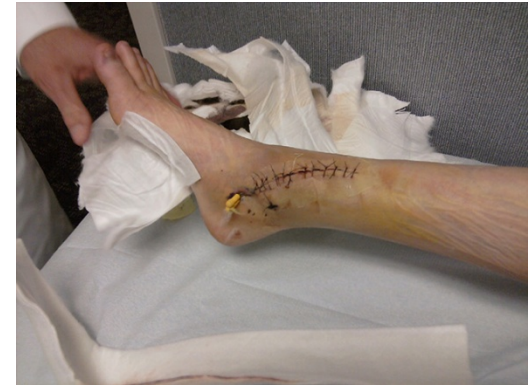Post-op Care

Grace's surgical wounds healed within a few weeks but she had to wear a cam walker fracture boot and was not allowed to participate in any sports for six weeks.

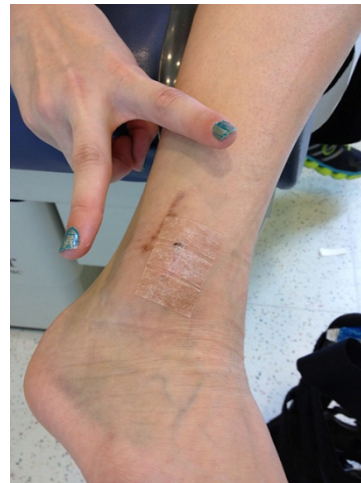
Grace's leg in a cast after surgery.



Grace's ankle after surgery with the dressings removed but sutures and pins still in place.



Grace's ankle after the sutures and pins were removed.




CONCLUSION

Four months after surgery, x-rays showed that Grace's right leg and ankle were normal and within a year her ankle had full range of motion with no pain or tenderness.

Since then, Grace has been doing very well and has returned to gymnastics and track. Grace still receives ongoing strengthening therapy and remains under observation for lower limb issues that might arise as a result of her previous injuries.

As this case shows, in some instances big problems can be resolved with minimally invasive procedures that allow kids to quickly recover and return to their sports and activities.



David S. Feldman, MD

Pediatric Orthopedic Surgeon

www.davidsfeldmanmd.com