

# Case Study: Stephanie

Severe Idiopathic Scoliosis

Age Range During Treatment: 13 years

**David S. Feldman, MD**

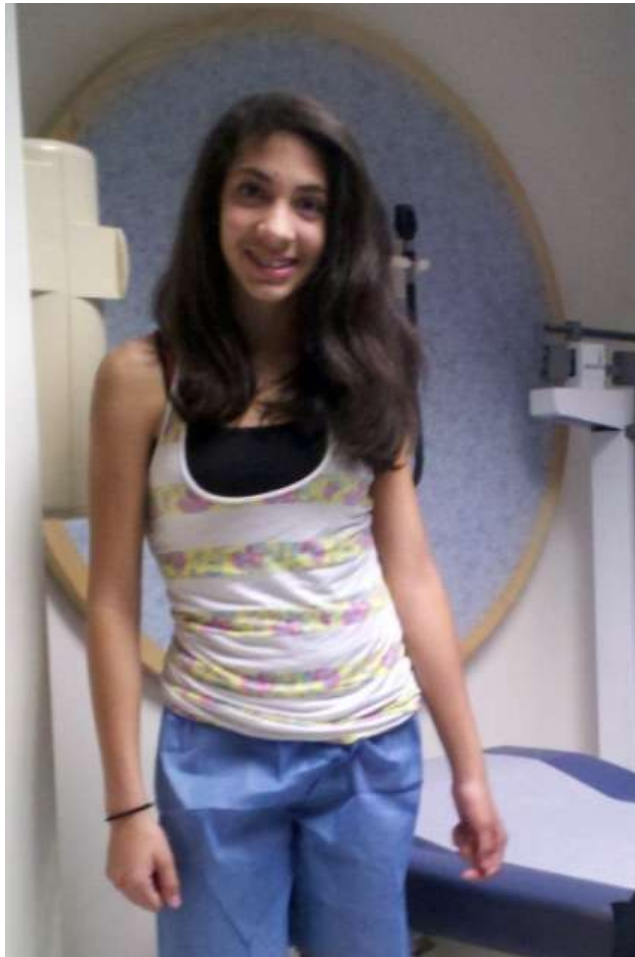Chief of Pediatric Orthopedic Surgery

Professor of Orthopedic Surgery & Pediatrics

NYU Langone Medical Center & NYU Hospital for Joint Diseases

# BACKGROUND

At the age of six, Stephanie was diagnosed with scoliosis. At the age of nine, a brief attempt was made to treat her curve with a brace but it was too uncomfortable for her to wear. A few months before her 12<sup>th</sup> birthday, her pediatrician advised that a spinal fusion was the best course of action.

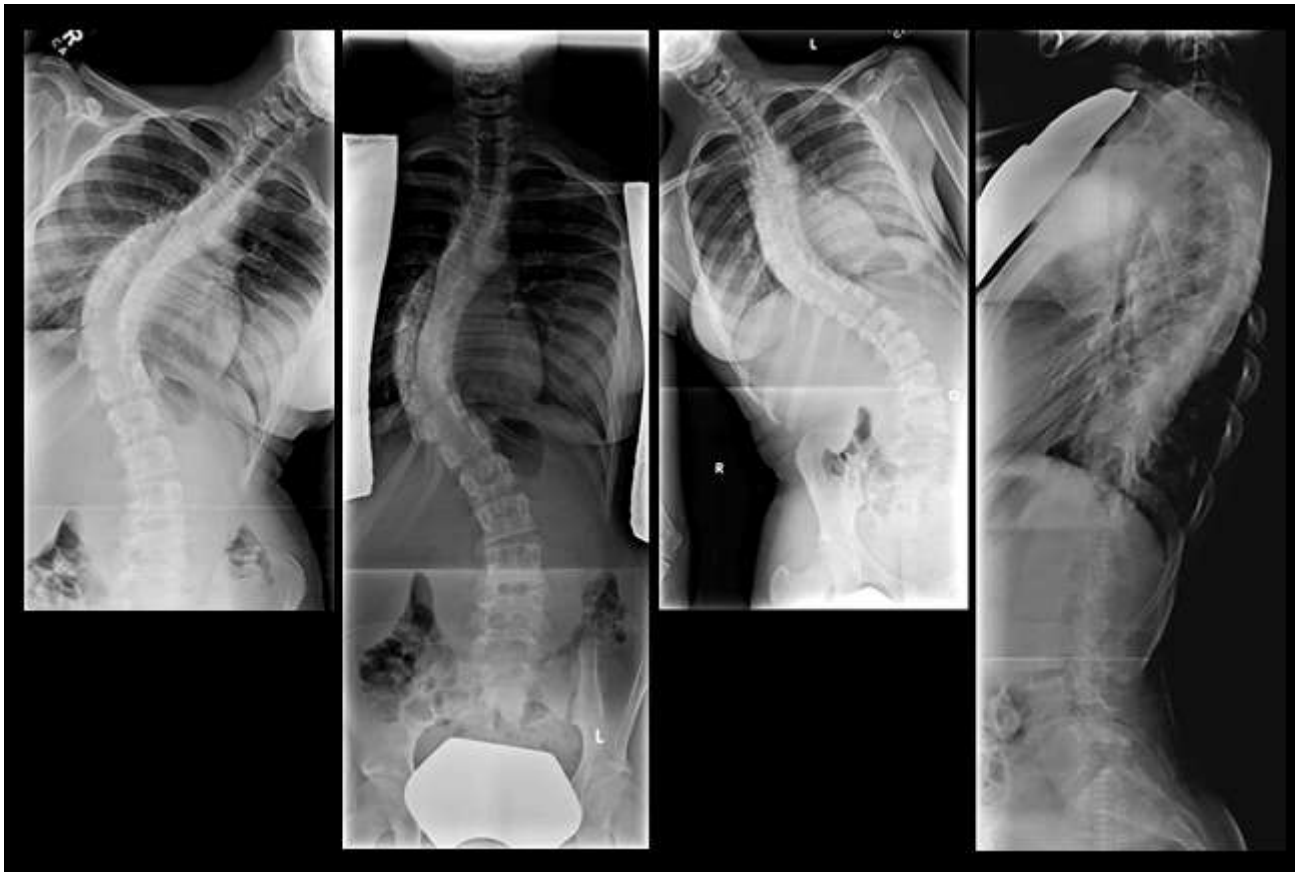

Stephanie during an early office visit.

# EVALUATION

During my examination I found that there was a large curve in Stephanie's spine and a significant right mid-thoracic prominence.

There was a 30 degree curve in her T1 – T5 vertebrae, a 61 degree curve in her T6 - T12 vertebrae, and a 28 degree curve in her L1-L4 vertebrae. She didn't have any skin markings and her shoulders were even.



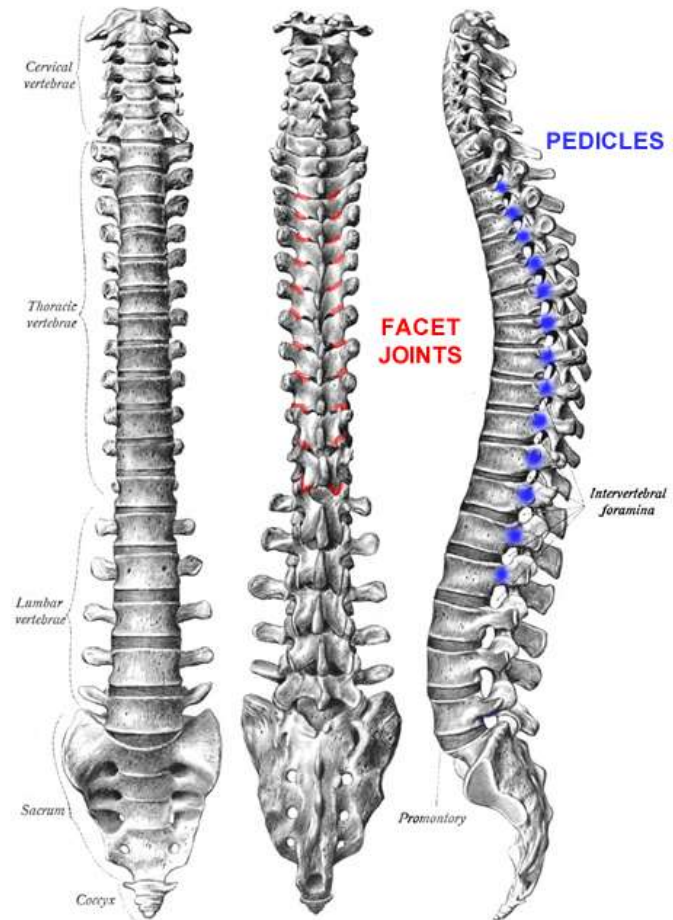
Pre-op x-rays of Stephanie's spine showing severe scoliosis in the thoracic vertebrae.

# TREATMENT

Scoliotic curves in the range of 20 to 40 degrees are considered moderate and curves over 40 degrees are considered severe. Given the presence of multiple curves and their severity, I agreed that surgical intervention was necessary.

# Posterior Spinal Fusion

An incision was made over Stephanie's spine from her T2 to L2 vertebrae. Screws were applied to the pedicles of each vertebra and facetectomies (removal of facet joints) were performed at all levels except for T1-T2 and L1-L2 to aid in fusion.



An illustration of Stephanie's spinal fusion and facetectomy sites.



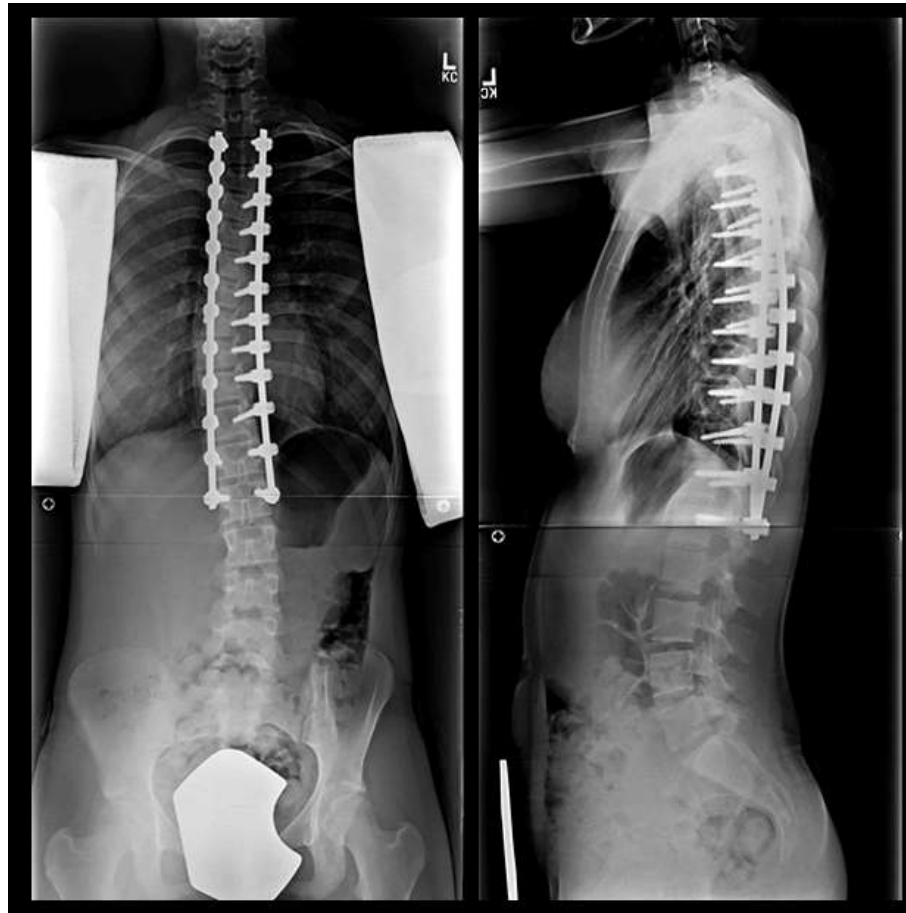Rods were then applied in the corrected position, the screws were tightened, and a thin layer of bone was removed from the spine (decortication) to allow the spine to fuse at these levels.

Bone grafts were then applied to the spine to encourage the growth of a solid bone bridge between the vertebrae to complete the spinal fusion.

The wound was closed in multiple layers by a plastic surgeon (to ensure the best possible cosmetic result and limit the risk of infection) and dry sterile dressings were applied.

# Results

Two months after surgery, Stephanie's surgical wound was well healed and x-rays showed her hardware was in proper position and her spine was properly aligned.



Post-op x-rays of Stephanie's spine which show her fusion hardware in place and her scoliosis well corrected.

Four months after surgery, Stephanie visited her pediatrician with complaints of lower back pain. X-rays were taken and her pediatrician suspected the pain was caused by a small lumbar spine fracture for which she prescribed six weeks of physical therapy.

# CONCLUSION

Since her surgery, Stephanie has returned to her regular activities without any restrictions. I believe this case is a clear example of treatment allowing patients to rapidly recover and return to their normal lives soon after scoliosis surgery. This is a considerable advancement from just 10 years ago.





**David S. Feldman, MD**

**Pediatric Orthopedic Surgeon**

**[www.davidsfeldmanmd.com](http://www.davidsfeldmanmd.com)**